

Subcutaneous Onlay Laparoscopic Approach versus Laparoscopic Intraperitoneal Onlay Mesh Repair for Paraumbilical Hernias: A Randomised Clinical Trial

JAYADHARSHINI KUMAR¹, ATHIRA GOPINATHAN², SIVAMARIESWARAN RAMALINGAM³, BALAMURUGAN RAMACHANDRAN⁴



ABSTRACT

Introduction: Paraumbilical hernias are currently treated most effectively with a minimally invasive strategy. After the introduction of Intraperitoneal Onlay Mesh Placement (IPOM), it has been performed as a traditional technique for paraumbilical hernias, though there are many techniques such as placement of mesh in the preperitoneal/retromuscular space or subcutaneous space. However, there has been a constant debate over the choice of a better approach.

Aim: To compare the short-term outcomes of IPOM and Subcutaneous Onlay Laparoscopic Approach (SCOLA) repair (subcutaneous onlay mesh placement) for paraumbilical hernias.

Materials and Methods: A randomised clinical trial was conducted in the Department of General Surgery, SRM medical college hospital and research centre, Chennai, Tamil Nadu, India, from March 2021 to August 2022. Study was conducted on patients undergoing laparoscopic hernia mesh repair for paraumbilical hernia. A total of 60 individuals were included in the study. They were placed in groups A and B according to block randomisation with concealed cover. Group A got laparoscopic SCOLA repair and group B got laparoscopic IPOM repair. The patients were tracked for a total of six months. A comparison of two groups was done to evaluate which technique

is superior over the other in terms of duration of hospitalisation, cost-effectiveness, duration of surgery, postoperative pain, postoperative complications, speed of recovery and returning to routine activity and recurrence.

Results: Total 60 participants were divided into two groups, 30 subjects each in group A and group B with a mean±Standard Deviation (SD) age of the subjects in SCOLA group and IPOM group was 37.50±8.41 years and 37.87±9.18 years, respectively. Laparoscopic SCOLA repair for paraumbilical hernia has a comparable outcome to the traditional laparoscopic approach like IPOM in terms of postoperative wound healing (p-value=0.25). A 6-month follow-up revealed no recurrence in either group. Being a newer procedure that requires extensive dissection, the operating time (p-value=0.001), seroma formation (p-value=0.057) and number of hospital days (p-value=0.001) were higher for SCOLA. Also, it was noted that patients who underwent IPOM had significantly more pain experienced as compared to those undergoing SCOLA (p-value 0.45, 0.01 and 0.66 on postoperative days 1, 3 and 5, respectively). Moreover, a significant advantage of SCOLA is its cost-effectiveness.

Conclusion: With the advantages of cost-effectiveness and lesser pain, SCOLA approach may be used more frequently in selected patients.

Keywords: Divarication of recti, Extensive dissection, Operating time, Seroma

INTRODUCTION

Paraumbilical hernia is described as an abnormal protrusion of a viscus through an acquired defect in the linea alba decussating fibres, either above or below the umbilicus [1]. It is more prevalent in women [2]. The predisposing factors include increase in abdominal pressure, multiparity, obesity, heavy work lifting and chronic cough. This is the second most typical type of ventral hernia, accounting for 0.3% of all hernia repairs in the United Kingdom (UK) and accounting for 15-18% of all surgical procedures in India [3].

Laparoscopic Ventral Hernia Repair (LVHR) started in 1993 by LEBLANC. Later evolutions were done making laparoscopic surgery safest and easier for repair of ventral hernia [4]. When compared to Open Ventral Hernia Repair (OVHR), "current evidence suggests that laparoscopic procedures provide advantages such as shorter duration of hospital stay, earlier return to work, reduced wound complication, including surgical site infection, and decreased recurrence rates" [5].

Laparoscopic ventral hernia repair, which requires minimal access surgery and is now the preferred method due to the development of new meshes, has a number of drawbacks, including the risk of bowel injury and potential for delayed complications after intraperitoneal

mesh placement, such as adherent small bowel obstruction, bowel erosion, and enterocutaneous fistula [6].

Delay in repair, on the other hand, might have significant clinical implications. Paraumbilical hernias cause discomfort and can lead to imprisonment or strangling of the small bowel, which is nearly always deadly [7].

Patients with hernias have a mixed outcomes. They have a significant recurrence rate. Infection, discomfort, and recurrence are all commonly reported issues. The chance of recurrence is significant with the presence of predisposing factors. Complications are bowel blockage, and strangling [8,9].

Treatment of paraumbilical hernias also has a significant financial burden. There is inconclusive evidence on if, how, or when to perform surgical intervention in such cases. The mesh is positioned intraperitoneally, preperitoneal/retromuscularly or subcutaneously during laparoscopic hernia repair. But it is still unclear which approach is better.

The advantages of SCOLA are lesser pain, elimination of intraperitoneal exploration and thereby avoiding complications such as bowel injury, adhesive colic, paralytic ileus and intestinal obstruction. It also provides the benefit of preserving fascial planes intact, for surgery in

future if necessary due to recurrence. It is cost-effective. It is found to be very useful procedure to repair the divarication of recti also. The disadvantages of SCOLA is seroma formation, longer duration to return to routine activity due to placement of drain in situ for longer duration [10-14].

The advantages of Intraperitoneal Onlay Mesh Placement (IPOM) is lesser hospital stay, no or very minimal seroma formation, shorter duration to return to routine activity. The disadvantages are more pain due to placement of tacker in the anterior abdominal wall, need for intraperitoneal exploration may lead to future complications related to bowel adhesion/bowel injury. Repair of recurrence if occurs will be difficult. Need for composite mesh and tackers is costly [14]. The present study aimed to compare the short-term outcomes of IPOM and SCOLA repair for paraumbilical hernias.

MATERIALS AND METHODS

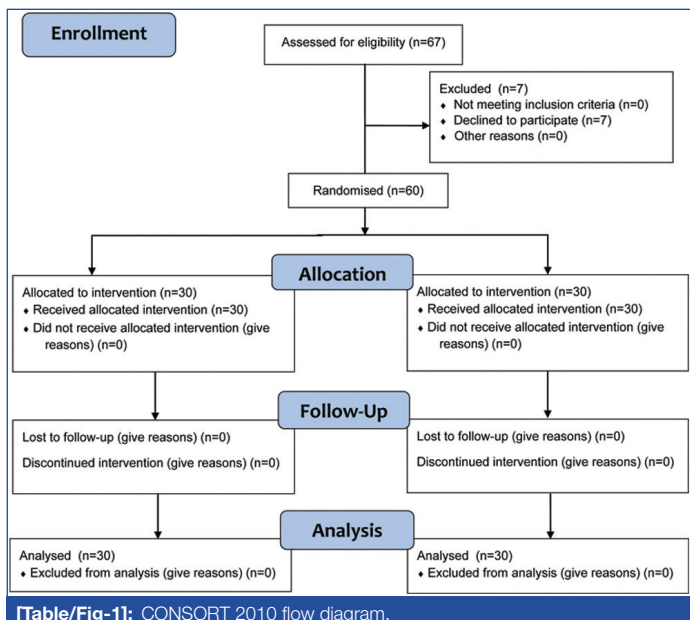
A randomised clinical trial was conducted in the Department of General Surgery, SRM medical college hospital and research centre, Chennai, Tamil Nadu, India, from March 2021 to August 2022. Study was conducted on patients undergoing laparoscopic hernia mesh repair for paraumbilical hernia. The study was conducted after obtaining clearance from the Institutional Ethical Committee (IEC approval number: 2388/IEC/2021) and consent from the patients.

Sample size calculation: The sample size calculation was based on a preliminary pilot trial including 20 patients. There should be a 20% difference in cost-effectiveness between the two groups for the study to have 80% power and alpha error at 0.05. A total of 22 patients in each group made up the sample size according to calculations. We chose to include 30 patients in each group to reduce attrition; the data from the pilot study were not used in the final analysis.

Inclusion criteria: Patients of both sexes of all age groups with clinically proven and radiologically diagnosed paraumbilical hernia, with hernia defect size less than 3 cm, reducible hernia and individuals who can safely have general anaesthesia were included in the study.

Exclusion criteria: Patients with hernia defect size more than 3 cm, irreducible hernia, recurrent and incarcerated/obstructed/strangulated hernia and those patients who are not fit for general anaesthesia were excluded from the study.

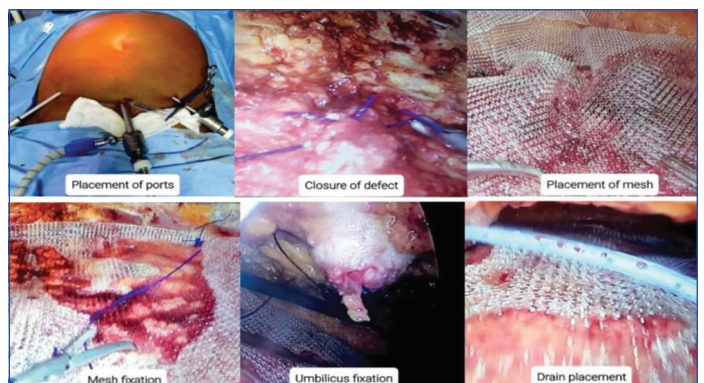
Patients were further divided in two groups with 30 patients in each group according to block randomisation with concealed cover. group A had laparoscopic Scola repair (n=30) and group B had laparoscopic Ipom repair (n=30). Both the groups were regularly tracked for six months and compared [Table/Fig-1].



All patients were subjected to thorough examination and extensive clinical history, physical examination, haematological investigation as per the need. Computed Tomography (CT) abdomen was done to assess the size of the defect and the contents of the sac.

Subcutaneous Onlay Laparoscopic Approach (SCOLA)

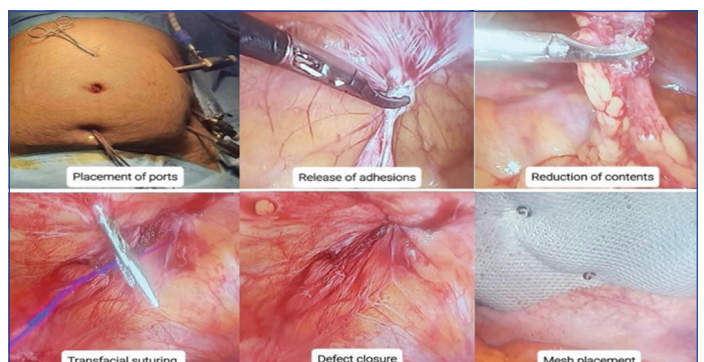
A transverse 2 cm incision was made 2 cm above the pubic symphysis. Subcutaneous tissue blunt dissection was carried out up to the anterior rectus sheath with fingers. Camera port was introduced into this incision. Subdermal purse string suture tightened to secure it. The subcutaneous space was insufflate to 15 mmHg. Two 5 mm working ports were inserted on either side of 10 mm camera port at midclavicular line. Dissection of subcutaneous tissue was done and flaps were raised between subcutaneous tissue and anterior rectus sheath all around the defect. Hernia contents were reduced. Hernia defect was closed using 1-0 prolene. A prolene mesh (size of 15x15 cm) was kept over the defect and secured with anterior rectus sheath using 1-0 prolene sutures. Umbilicus fixed with anterior rectus sheath using 1-0 prolene. Two 16 French suction drain was placed over the mesh using the 5 mm ports and secured. Skin was approximated using 3-0 ethilon. Postoperatively drain was retained until it drains less than 50 mL per day [Table/Fig-2].



[Table/Fig-2]: Placement of ports, closing of defect, placing of simple prolene mesh in subcutaneous plane and securing with 1-0 prolene, fixation of umbilicus and placement of drain in SCOLA.

Laparoscopic Intraperitoneal Onlay Mesh Repair (IPOM)

The camera port was inserted at Palmer's point. Two 5 mm working port was inserted in the left lumbar region and in the left iliac fossa, respectively. The contents of the hernial sac were reduced into the peritoneal cavi. The suture passer was passed on either side of the defect and closed by transfascial sutures. A 15x15 cm dual mesh was placed circumferentially covering the defect and fixed by approximately 20 tacks [Table/Fig-3].



[Table/Fig-3]: Placement of ports, release of adhesions and reduction of contents, the closing of defect using transfascial sutures, placing of composite mesh in the anterior abdominal wall and securing with tackers in IPOM.

Postoperatively, patient was assessed and then regularly followed-up for a period of six months. In the immediate postoperative period, duration of surgery (time was recorded from start of skin incision till skin closure), postoperative pain as per Visual Analog

Scale (VAS) scale [15], seroma formation, duration of hospital stay, time taken to resume normal activities and complications such as surgical site infection, wound dehiscence were assessed. The patient was duly followed-up for assessment of wound healing as per the Southampton wound scoring system [16].

STATISTICAL ANALYSIS

Data was analysed statistically using Statistical Package for the Social Sciences (SPSS) software, Microsoft Excel and Python 2.0. The categorical data was expressed as frequency and percentage. Whereas, continuous variables in terms of mean and standard deviation. Chi-square test was used to compare the results of two groups. The results were expressed in 85% confidence interval. A p-value <0.05 considered to be statistically significant.

RESULTS

It was observed that 45 patients (75%) were in the age group between 22-43 years, in both the groups. It was observed 33 (55%) patients were females and 27 (45%) patients were males in both groups [Table/Fig-4].

The mean age of the subjects in SCOLA and IPOM group was 37.50±8.41 years and 37.87±9.18 years, respectively [Table/Fig-5].

Age group (in years)	Group A		IPOM		Total (n)
	Males (n)	Females (n)	Males (n)	Females (n)	
22-33	7	3	6	5	21
34-43	6	7	5	6	24
44-53	0	6	1	4	11
54-63	1	0	1	2	4
Total	14	16	13	17	60

[Table/Fig-4]: Age and gender distribution across two age groups.

Particulars	Mean±Standard deviation (years)
Group A	
Male (1)	34.07±8.53
Female (2)	40.50±7.28
Overall	37.50±8.41
Group B	
Ipom- Male (1)	36.38±8.24
Ipom- Female (2)	39.00±9.92
Ipom-Overall	37.87±9.18

[Table/Fig-5]: Mean and dispersion of age across two groups.

Subcutaneous onlay laparoscopic approach as a procedure required more operative time (Mean±SD: 99.13±10.62 minutes) when compared to IPOM (Mean±SD: 71.87±9.41 minutes) [Table/Fig-6].

Duration of surgery (in minutes)	Group A		Group B		p-value
	No. of subjects	%	No. of subjects	%	
<80	1	3%	26	87%	0.001
81-90	4	13%	3	10%	
91-100	16	53%	1	3%	
101-110	4	13%	0	0%	
>111	5	17%	0	0%	
Total	30	100%	30	100%	
Mean±SD (in minutes)	99.13±10.62		71.87±9.41		

[Table/Fig-6]: Comparison of duration of surgery across two groups. p-value in bold font indicates statistically significant values

The mean hospital stay was expectedly higher in SCOLA patients (8.2±1.39 days) as compared with patients who underwent IPOM (4.07±1.23 days) [Table/Fig-7].

Hospital stay (in days)	Group A		Group B		p-value
	No. of subjects	%	No. of subjects	%	
1-3 days	0	0%	10	33%	0.001
4-7 days	10	33%	20	67%	
8-10 days	19	63%	0	0%	
11-14 days	1	3%	0	0%	
Total	30	100%	30	100%	
Mean±SD	8.2±1.39 days		4.07±1.23 days		

[Table/Fig-7]: Comparison of hospital stay duration across two groups. *Chi-square test was used to determine the p-value

The patients were followed-up for a period of six months, and no recurrence was noted in either group. It was noted that patients who underwent IPOM had significantly more pain experienced as compared to those undergoing SCOLA [Table/Fig-8].

Age group (years)	POD 1		POD 3		POD 5	
	Group A	Group B	Group A	Group B	Group A	Group B
22-33	6.10	6.45	3.80	5.55	2.60	3.00
34-43	6.69	7.09	4.38	5.36	2.77	2.91
44-53	6.00	6.40	4.17	4.80	2.50	2.80
54-63	5.00	7.00	4.00	5.33	2.00	3.00
p-value between Group A and Group B on POD 1, POD 3 and POD 5	0.45		0.01		0.66	

[Table/Fig-8]: Average pain scores across different age groups for group A and group B. POD: Postoperative day

The mean score in the SCOLA group was 1.33±0.61, and in the IPOM group was 1.17±0.46 [Table/Fig-9].

It can be observed that the Seroma occurrence is very low in IPOM (3.33%) as against the SCOLA (23.33%) [Table/Fig-10].

The days taken to return to normal activity is relatively lower in IPOM than SCOLA groups [Table/Fig-11].

Wound healing score	Group A		Group B	
	No. of subjects	%	No. of subjects	%
1	22	73%	26	87%
2	6	20%	3	10%
3	2	7%	1	3%
Total	30	100%	30	100%
Mean±SD	1.33±0.61		1.17±0.46	
p-value	0.25			

[Table/Fig-9]: Comparison of wound healing across two groups.

Seroma	Group B		Group A	
	No. of patients	%	No. of patients	%
Absent	29	96.67%	23	76.67%
Present	1	3.33%	7	23.33%
Total	30	100.00%	30.00	100.00%
p-value	0.057			

[Table/Fig-10]: Comparison of seroma across two groups.

Group	Mean	SD
Group B	1.6	0.46
Group A	5.2	0.77
T value	4.67	
p-value	<0.001	

[Table/Fig-11]: Mean duration of return to normal activity in days across two groups.

It can be observed that the Surgical Site Infection (SSI) score is relatively low in both groups being 3.33% and 6.67% in SCOLA and IPOM groups, respectively [Table/Fig-12].

SSI	Group A		Group B	
	No. of patients	%	No. of patients	%
Absent	29	96.67%	28	93.33%
Present	1	3.33%	2	6.67%
Total	30	100.00%	30.00	100.00%
p-value	1.00			

[Table/Fig-12]: Comparison of SSI across two groups.

Cost analysis: The present study hospital does not charge for beds, investigations, medications, or surgery. So here authors are comparing only for the implants. For SCOLA, authors used 15×15 cm prolene mesh. The maximum retail price of lotus 15×15 cm prolene mesh cost Rs. 4092 which is fixed by 1-0 prolene cost Rs. 328. Romovac suction drain tube 16Fr costs Rs. 978. For ipom we use 15×15 cm composite mesh and tackers. The maximum retail price of lotus 15×15 cm composite mesh was Rs. 36180 which was fixed by tackers costs Rs. 25188. Total cost for ipom is Rs. 61368. Therefore, it can be observed that SCOLA procedure is coming to one-tenth of the cost of an IPOM procedure [Table/Fig-13].

Method	Group A	Group B
Mesh	Rs. 4092	Rs. 36180
Fixation	Rs. 328	Rs. 25188
Drain tube	Rs. 978	Not applicable
Total	Rs. 5398	Rs. 61368

[Table/Fig-13]: Cost-analysis across two groups.

DISCUSSION

A study in the United States (US) on scola for ventral hernias elicited higher rates of postoperative complication in patients with an increased Body Mass Index (BMI) and hence patient selection and preoperative counselling will prevail on the final patient outcome [10]. It also states that it has an advantage of avoiding the laparoscopic complications such as enterotomy, bowel resection and also provides the benefit of preserving fascial planes intact for surgery in future in case if necessary due to recurrence. This study has infected seroma as a complication for one patient. This study sought for additional prospective data collection to allow future comparison of long-term outcomes compared to more established approaches such as open sublay or laparoscopic IPOM repairs. In the present study, authors compared the scola with the traditional approach IPOM in terms of which technique is superior over the other. Authors found In terms of minimal recurrence and postoperative wound healing, the results are comparable. The present study did not include the BMI as confounding factor. However, the elimination of the intraperitoneal exploration does exclude the possibility of rare complications like bowel perforation and the more common ileus or obstruction secondary to adhesions, and hence SCOLA approach may be used more frequently in selected patients. No such infective seroma was found in the present study. Suture site granuloma was noted in one case.

One study done in Chennai, India in 2019 had mean operative time as 150 minutes with seroma being the most common complication and was aspirated once [13]. This study has not mentioned about the expertise of the surgeon. In present study, mean duration of surgery is 99 minutes. Only one single senior experienced surgeon has done all the cases. Authors found seroma formation in seven patients and was managed conservatively with abdominal binder application and followed-up, found to decrease over a period of one week.

Patients with ventral hernias associated with diastasis of the rectus abdominus muscle have the SCOLA procedure as a safe, reliable, and effective alternative as first described in 2018 [14]. It showed mean operating time was 93.5 minutes and had one recurrence on follow-up of eight months. In the present study no recurrence was noted on follow-up of six months. A few studies have also approached the use of SCOLA in diastases of abdominal wall with varying success rates, and concluded that it is a promising alternative if suitable results can be obtained [15]. Authors did not take patients with divarication of recti for this study to make the SCOLA more comparable with IPOM.

One study published in 2022 shows that "SCOLA is an efficient procedure for the treatment of umbilical/epigastric hernia with diastasis recti with minimal complications and postoperative morbidity. The technique gives an acceptable cosmetic result to patients". They further described seroma formation up to 80%, but also described a modification to reduce the seroma formation: change in the operating ports and also using spinal needles to limit the lateral dissection, thereby reducing the amount of dissection [14]. In the present study, seroma formation was noted up to 23% of study population and presence of drain tube has delayed the time required to return to normal activity. This appears to be a challenge faced by most studies focusing on the SCOLA approach owing to the extensive dissection in the subcutaneous plane [14,16].

Many researchers have noted the cost-effectiveness of SCOLA in view of using a simple prolene mesh as compared to a dual side mesh in IPOM procedure [13,16]. In the present study, In place of IPOM procedure which requires a dual side mesh and tackers, a simple prolene mesh was used in the SCOLA procedure being in the subcutaneous plane, almost coming to one-tenth of the cost of an IPOM procedure.

More feasible studies and long-term follow-ups need to be done to truly assess the impact of SCOLA approach, and whether it can really be pathbreaking in the world of ventral hernia repairs.

Limitation(s)

The key limitation of the study was the small sample size to perform stratified analysis. Another shortcoming was difficulty in evaluating and comparing the frequency of recurrence in both groups due to shorter duration of the study.

CONCLUSION(S)

On analysing the data, the present study clearly shows that SCOLA approach has a comparable outcome to the traditional laparoscopic approach like IPOM. In terms of minimal recurrence and postoperative wound healing, the results are comparable. Seroma formation and operating duration was more. Cost-effectiveness and lesser pain were noted in SCOLA. More pain in IPOM procedure may be due to the application of tackers over anterior abdominal wall, and no such appliance being used in SCOLA.

Acknowledgement

The Authors would like to express their gratitude to SRMIST, Kattankulathur, TN, India 603203. The centre where the study was conducted in entirety for the support in providing clinical setup, imaging and laboratory services.

REFERENCES

- [1] Malarvizhi C. Anterior Abdominal Wall Hernia in Women (Doctoral dissertation, Kilpauk Medical College, Chennai).
- [2] Bedewi MA, El-Sharkawy MS, Al Boukai AA, Al-Nakshabandi N. Prevalence of adult paraumbilical hernia. Assessment by high-resolution sonography: A hospital-based study. *Hernia*. 2012;16:59-62.
- [3] Sangwan M, Sangwan V, Garg M, Mahendirutta P, Garg U. Abdominal wall hernia in a rural population in India-Is spectrum changing? *Open Journal of Epidemiology*. 2013;3:135-38.
- [4] LeBlanc KA, Booth WW. Laparoscopic repair of incisional abdominal hernias using expanded polytetrafluoroethylene: Preliminary findings. *Surgical Laparoscopy & Endoscopy*. 1993;3(1):39-41.

- [5] Misiakos EP, Machairas A, Patapis P, Liakakos T. Laparoscopic ventral hernia repair: Pros and cons compared with open hernia repair. *JSLs: Journal of the Society of Laparoendoscopic Surgeons*. 2008;12(2):117.
- [6] Brown CN, Finch JG. Which mesh for hernia repair? *The Annals of the Royal College of Surgeons of England*. 2010;92(4):272-78.
- [7] Bucknall TE, Cox PJ, Ellis H. Burst abdomen and incisional hernia: A prospective study of 1129 major laparotomies. *Br Med J (Clin Res Ed)*. 1982;284(6320):931-33.
- [8] Azin A, Hirpara D, Jackson T, Okrainec A, Elnahas A, Chadi SA, et al. Emergency laparoscopic and open repair of incarcerated ventral hernias: A multi-institutional comparative analysis with coarsened exact matching. *Surgical Endoscopy*. 2019;33(9):2812-20.
- [9] Petersson J, Koedam TW, Bonjer HJ, Andersson J, Angenete E, Bock D, et al. Bowel obstruction and ventral hernia after laparoscopic versus open surgery for rectal cancer in a randomised trial (COLOR II). *Annals of Surgery*. 2019;269(1):53-57.
- [10] Dong CT, Sreeramaju P, Pechman DM, Weithorn D, Camacho D, Malcher F. SubCutaneous OnLay endoscopic Approach (SCOLA) mesh repair for small midline ventral hernias with diastasis recti: An initial US experience. *Surgical Endoscopy*. 2021;35(12):6449-54.
- [11] Naidu PS, Pai V, Rahman K. Subcutaneous onlay laparoscopic approach for ventral hernias-a case series. *Journal of Dental and Medical Sciences*. 2019;18(5):04-07.
- [12] Claus CM, Malcher F, Cavazzola LT, Furtado M, Morrell A, Azevedo M, et al. Subcutaneous onlay laparoscopic approach (SCOLA) for ventral hernia and rectus abdominis diastasis repair: Technical description and initial results. *ABCD: Arquivos Brasileiros de Cirurgia Digestiva (São Paulo)*. 2018;31(4):e1399.
- [13] Coco D, Leanza S. Is subcutaneous laparoscopic recti abdominis repair (SCOLA) a safe approach to repair diastasis of the rectus abdominis muscles (DMRA)? A brief review. *Medical Studies/Studia Medyczne*. 2022;38(3):221-25.
- [14] Shinde PH, Chakravarthy V, Karvande R, Mahadik K, Gandhi J. A novel modification of subcutaneous onlay endoscopic repair of midline ventral hernias with diastasis recti: An Indian experience. *Cureus*. 2022;14(6):e26004.
- [15] Langley GB, Sheppard H. The visual analogue scale: Its use in pain measurement. *Rheumatology International*. 1985;5(4):145-48.
- [16] Alam SI, Khan MY, Gul A, Jan QA. Surgical site infection: Frequency after open cholecystectomy using southampton wound scoring system in surgical unit Khyber teaching hospital Peshawar. *The Professional Medical Journal*. 2014;21(02):377-81.

PARTICULARS OF CONTRIBUTORS:

1. Student (Postgraduate), Department of General Surgery, SRM Medical College Hospital and Research Centre, Kattangulathur, Chennai, Tamil Nadu, India.
2. Associate Professor, Department of General Surgery, SRM Medical College Hospital and Research Centre, Kattangulathur, Chennai, Tamil Nadu, India.
3. Assistant Professor, Department of General Surgery, SRM Medical College Hospital and Research Centre, Kattangulathur, Chennai, Tamil Nadu, India.
4. Professor, Department of General Surgery, SRM Medical College Hospital and Research Centre, Kattangulathur, Chennai, Tamil Nadu, India.

NAME, ADDRESS, E-MAIL ID OF THE CORRESPONDING AUTHOR:

Dr. Athira Gopinathan,
Plot 247, Abhis Aradhana, E-block, 3rd Cross Street, Parvathi Nagar South,
Madambakkam, Chennai-600126, Tamil Nadu, India.
E-mail: athirag@srmist.edu.in

PLAGIARISM CHECKING METHODS: [\[Jain H et al.\]](#)

- Plagiarism X-checker: Nov 21, 2022
- Manual Googling: Mar 16, 2023
- iThenticate Software: Apr 05, 2023 (5%)

ETYMOLOGY: Author Origin

AUTHOR DECLARATION:

- Financial or Other Competing Interests: None
- Was Ethics Committee Approval obtained for this study? Yes
- Was informed consent obtained from the subjects involved in the study? Yes
- For any images presented appropriate consent has been obtained from the subjects. Yes

Date of Submission: **Nov 03, 2022**

Date of Peer Review: **Dec 27, 2022**

Date of Acceptance: **Apr 10, 2023**

Date of Publishing: **May 01, 2023**